

Developmental dysplasia of the hip (DDH)

ORTHOPAEDIC FACT SHEET

Developmental dysplasia of the hip (DDH) is a condition that affects the hip joint in babies and young children. The hip is a ball-and-socket type joint, formed by the round 'head of femur' and a cup-shaped socket (acetabulum) (Figure 1). The normal infant hip is not mature at birth but develops into a strong and stable joint as the child grows. In DDH the hip does not develop normally.

DDH can vary from mild to severe. The socket may be shallow, and the structures that support the head of femur may be lax (Figure 2). This may allow the head of femur to be unstable. In more severe cases, the head of femur may lose contact with the socket. This is known as a dislocated hip (Figure 3), and is believed to occur in around one in 1000 infants.

Infants with DDH are not always born with the condition. It may develop in the weeks or months after birth. One or both hips can be affected. DDH is not painful in babies and young children; however, untreated DDH can result in hip pain and early development of osteoarthritis.

DDH is more likely to occur in girls, if there is a family history of DDH, in a first pregnancy, if the baby is breech, and in twins.

Signs of DDH may include stiffness of the hip, uneven positioning of the legs, one leg appearing shorter than the other, and uneven thigh or buttock creases. Sometimes the signs are hard to see, even by a doctor.

A hip ultrasound is used to confirm DDH in babies under six months old. After six months a hip x-ray is more useful.

Treatment depends on the child's age and the severity of the condition. Young babies with DDH are usually treated in an 'abduction brace', which holds the legs apart. This helps the socket to deepen and the hip to become stable with growth.

Early diagnosis and treatment is best, since late diagnosis often requires surgical treatment and can mean a higher likelihood of ongoing hip problems.

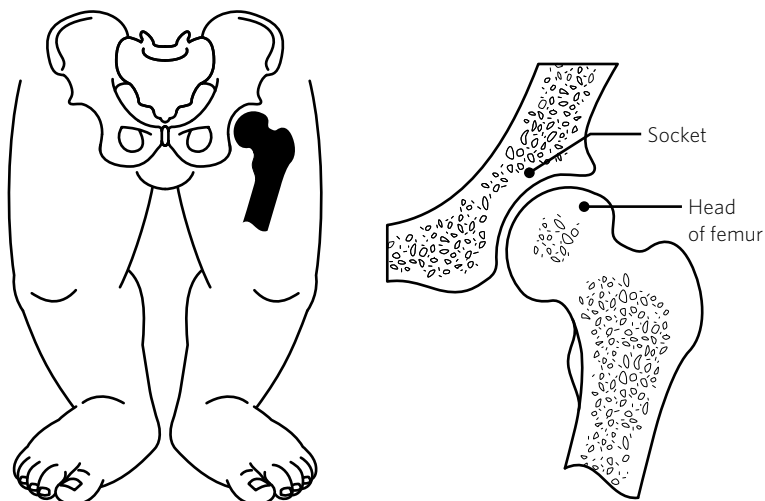


Figure 1. The normal infant hip

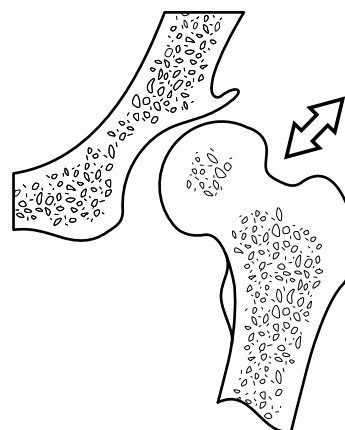


Figure 2. Developmental dysplasia of the hip with unstable head of femur

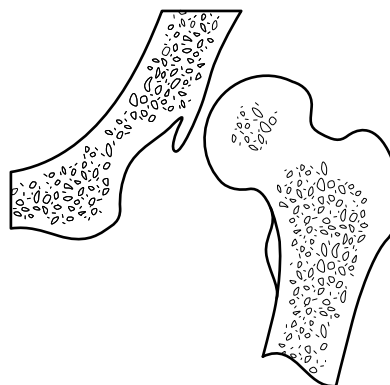


Figure 3. Developmental dysplasia of the hip with dislocated head of femur