

Surgery for dislocated hip in babies

ORTHOPAEDIC FACT SHEET

Developmental dysplasia of the hip (DDH) is a condition that affects the hip joint in babies and young children. The hip is a ball-and-socket type joint, formed by the round 'head of femur' and a cup-shaped socket (acetabulum) (Figure 1). In DDH the hip does not develop normally.

DDH can vary from mild to severe. The socket may be shallow, and the structures that support the head of femur may be lax. This may allow the head of femur to be unstable. In more severe cases, the head of femur may lose contact with the socket. This is known as a dislocated hip (Figure 2), and is believed to occur in around one in 1000 infants.

Young infants with hip dislocation are usually treated with a hip brace or harness. Surgery may be necessary if brace treatment is unsuccessful, or if a hip dislocation is first noticed when the child is older.

The hip is examined under general anaesthetic. A fluid that can be seen under x-ray is injected into the hip joint. This helps the orthopaedic surgeon to determine the best position of the femoral head in relation to the socket. The baby is then fitted in a special plaster cast known as a hip spica for around six weeks (Figure 3). This procedure is called a closed reduction (or closed relocation).

When the spica is removed, the hip is examined again under general anaesthetic. If the hip is stable, the child will wear a brace for a period of time (Figure 4). If the hip is still unstable, a hip spica is fitted for another six weeks before fitting the brace.

Sometimes an open reduction is required. This operation involves a small incision in the groin. Tight structures around the hip joint are released to allow the femoral head to be positioned correctly. This will be followed by spica and brace treatment.

In a late diagnosis of DDH (when the child is 18 months and older), more extensive surgery is usually required.

A serious complication of surgery for a dislocated hip is a growth problem of the head of femur (avascular necrosis). This may not be evident until the child is older. Ongoing follow-up by an orthopaedic surgeon is essential for all children who have had surgery for a dislocated hip.

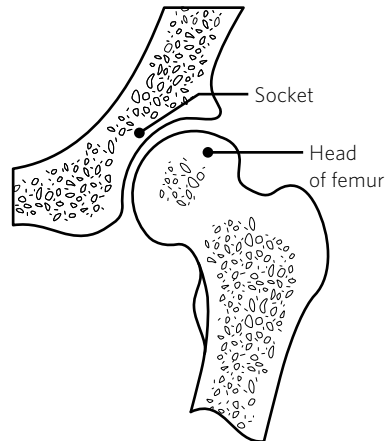


Figure 1. The normal infant hip

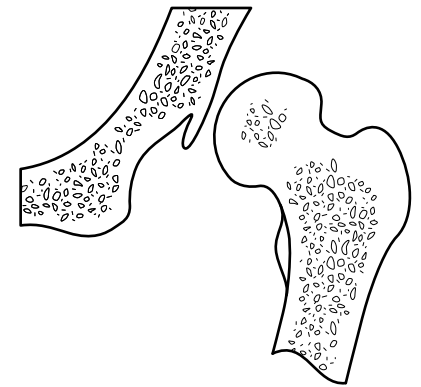


Figure 2. Dislocated hip

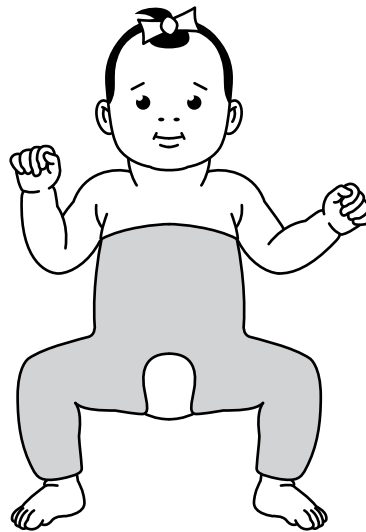


Figure 3. Hip spica after surgery

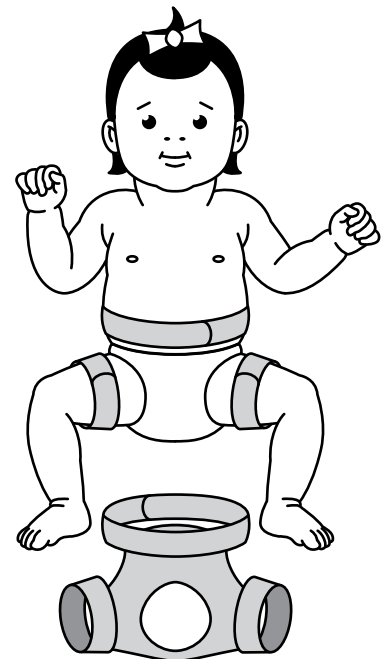


Figure 4. Hip abduction brace for older babies